

Moroccan Clinical Case



Dr M Maamar
Department of Internal Medicine
Med V University Rabat MOROCCO

ESIM 4-10 july 2010

- ✦ A 63-year-old Moroccan woman
- ✦ 6 month story of dyspnoea and headache
- ✦ Past medical history
 - asthma for 10 years
 - hydatid cyst of the liver in 1998.

✦ On physical examination

- BP 140/70 mmHg HR 70
- an infiltrated purpura in lower extremities
- wheezing in both fields,
- absent tendon reflexes in lower limbs
- sensory involvement in lower limbs

no fever and peripheral pulse are all present

✦ Laboratory tests

- ESR 130 mm first hour
- CRP 38 mg/l (<6 mg/l)
- Fibrinogen 6 g/l (2-4 g/l)
- EPP serum poly hypergamma 24 g/l (9-13 g/l)

- Full blood count :
 - Hg 7.5 g/dl
 - MCV 80 fl
 - Reticulocyt count 47 X10 (100-120)
 - Plts 730 /mm³ (150 – 450)
 - White blood cells 10
 - Neutrophil 4.3
 - Lymphocyt 3.6
 - Eosinophil 0.95 (0.1-0.5)

- Renal failure GFR 30ml/min
- Urea 3 mmol/l (3-8.5)
- Creatinemia 160 μ mol/l (45 -100)

- Urinalysis
- Microscopic haematuria 20 000 cell /mm³
- Proteinuria 2.5 g/24Hr

- Electromyography: Axonal polyneuropathy of the 4 limbs
- CT brain normal
- CT maxillary sinusitis
- CT thorax interstitial changes
- Skin biopsy leukocytoclastic vasculitis

What are the differential
diagnoses?

- Temporal arteritis ?

Temporal artery biopsy normal

Ocular examination normal

- Neoplasia ?

CT thorax no tumor

Abdominal echography normal

➔ vasculitis of small vessels

- Cryoglobulinemia
negative
no glomerulonephritis at renal biopsy.
- Microscopic polyangiitis
p-ANCA +
no glomerulonephritis at renal biopsy

- Polyarteritis nodosa ?

Neuropathy

Renal failure

RMN angiography No micronevrysm

No necrosis or vasculitis at renal and nervous biopsy

- Wegener granulomatosis ?

maxillary sinusitis

c-ANCA –

No granulom, no necrosis and no vasculitis

Final diagnosis

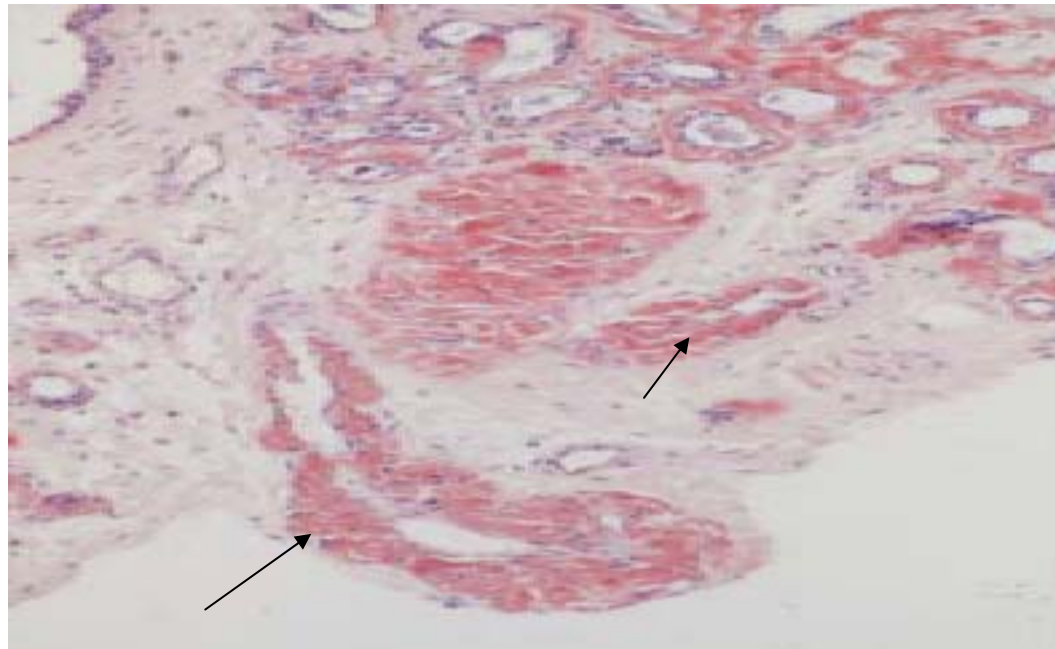
- Churg-Strauss syndrome
 - Hypereosinophilia
 - Asthma
 - Maxillary sinusitis
 - Neuropathy
 - pANCA +

Why renal injury ?

✦ Renal biopsy

No vasculitis or glomerulonephritis

Amyloïdosis AA



Summary

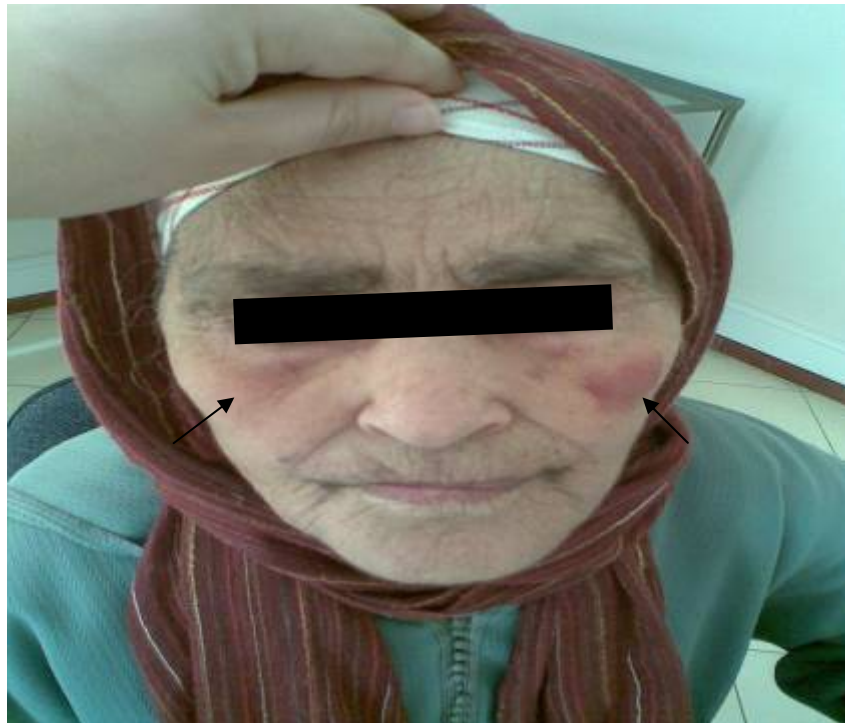Churg Strauss and Amyloidosis AA

✦ Treatment

- Pulse of methylprednisolone followed by oral steroids 1 mg/kg/day with a good response
- Captopril

✦ 6 months later

- Eosinophilia 0.3 elts/mm³ (0.1-0.5)
- Proteinuria 2.4 g/day



Review of literature

- - ✦ Amyloidosis AA rare (4.5/1M /year)
 - ✦ Inflammatory diseases
 - Rhumatoïd arthritis 7 - 23%
 - Périodic disease
 - Crohn disease, SPA
 - ✦ Infectious diseases

Amylose AA and vasculitis

- Vasculitis of large vessels
Temporal arteritis
- Behcet disease
- Rare cases secondary of microscopic polyangeitis, PAN and isolated skin vasculitis
- One case of conjonctival amyloidosis complicated Chrug Strauss syndrome



Thank you very much for your attention